

# ANTICANCER RESEARCH

International Journal of Cancer Research and Treatment

ISSN: 0250-7005

Volume 27, Number 4C, July-August 2007

## Contents

### *Clinical Studies*

- Pharmacoanalytical Assays of *Erwinia* Asparaginase (Erwinase) and Pharmacokinetic Results in High-risk Acute Lymphoblastic Leukemia (HR ALL) Patients: Simulations of Erwinase Population PK-PD Models. V.I. AVRAMIS, S. MARTÍN-ARAGÓN, E.V. AVRAMIS, B.L. ASSELIN (*Los Angeles; Davis, CA; Rochester, NY, USA; Madrid, Spain*) ..... 2561
- Fibrosarcoma of the Jaws: Two Cases of Primary Tumors with Intraosseous Growth. F. ANGIERO, T. RIZZUTI, R. CRIPPA, M. STEFANI (*Milan, Italy*) ..... 2573
- Expression of Endostatin in Merkel Cell Carcinoma. H. KUKKO, V. KOLJONEN, P. LASSUS, E. TUKIAINEN, C. HAGLUND, T. BÖHLING (*Helsinki, Finland*) ..... 2583
- Expression of Vascular Endothelial Growth Factor Receptor-2 in Merkel Cell Carcinoma. H. KUKKO, V. KOLJONEN, P. LASSUS, E. TUKIAINEN, C. HAGLUND, T. BÖHLING (*Helsinki, Finland*) ..... 2587
- Urinary Cyclic GMP after Treatment of Gynecological Cancer. A Prognostic Marker of Clinical Outcome. A. ØRBO, M. HANEVIK, R. JÆGER, S. VAN HEUSDEN, G. SAGER (*Tromsø, Norway*) ..... 2591
- Phase I Study of Docetaxel (TXT) and 5-Fluorouracil (5-FU) with Concurrent Radiotherapy in Patients with Advanced Esophageal Cancer. J. HIHARA, K. YOSHIDA, Y. HAMAI, M. EMI, Y. YAMAGUCHI, K. WADASAKI (*Hiroshima, Japan*) ..... 2597
- Significance of Thymidine Phosphorylase in Metronomic Chemotherapy using CPT-11 and Doxifluridine for Advanced Colorectal Carcinoma. Y. OGATA, T. SASATOMI, S. MORI, K. MATONO, N. ISHIBASHI, Y. AKAGI, T. FUKUSHIMA, H. MURAKAMI, M. USHIJIMA, K. SHIROUZU (*Kurume, Japan*) ..... 2605

Contents continued on the back cover

## Vertical Platysma Myocutaneous Flap Reconstruction for T2-staged Oral Carcinoma

DAVIDE PAGANI<sup>1</sup>, PASQUALE CAPACCIO<sup>1</sup>, WALTER FONTANELLA<sup>1</sup>, GIUSEPPE SAMBATARO<sup>1</sup>, GUIDO BROICH<sup>2</sup> and LORENZO PIGNATARO<sup>1</sup>

<sup>1</sup>Department of Otorhinolaryngological and Ophthalmological Sciences, Fondazione IRCCS Ospedale Maggiore Policlinico, Mangiagalli e Regina Elena, University of Milan;

<sup>2</sup>General Director, Local Health Unit, National Health Service Lodi, Italy

**Abstract.** *The surgical resection of tumour-affected oral soft tissue structures often leads to tissue defects. Various techniques can be used for reconstruction. Our experience of using a vertical platysma myocutaneous flap in a group of patients who underwent reconstruction after T2-staged oral cancer surgical resection associated with neck dissection is described. Only one patient required a surgical revision, due to flap detachment, with a pectoralis major myocutaneous flap. No other major complications, such as nerve lesions or orocutaneous fistulas, were observed. Satisfactory swallowing function was achieved within two weeks in all cases. A platysma myocutaneous flap is a versatile, easy-to-perform, one-stage procedure, and the outcome is best in adequately selected patients; it should not be adopted in patients who have undergone previous neck surgery or radiotherapy, or if radical neck dissection is planned. Care is required to preserve the external jugular vein and the submental artery, particularly when level I is dissected.*

The aim of cancer surgery is to resect the tumour and leave tumour-free surgical borders. In the case of oral cancers, the surgical resection of tumour-affected structures often leads to defects in the oral, oropharyngeal and maxillofacial soft tissues, and key aspects of the management of such patients are cosmetic reconstruction and restoration of swallowing function. Various techniques can be used to reconstruct soft tissue defects, including primary closure, skin grafts, pedicle myocutaneous flaps and microvascular-free flaps. Although

the emphasis seems to have shifted to radial forearm flaps over recent years (1), in selected cases a platysma myocutaneous flap still provides an interesting reconstructive option when direct closure is not possible.

The first paper describing a platysma myocutaneous flap was published by Delpech in 1823; the flap was rotated 180° and used to repair a lower lip defect, but it necrosed, probably because of excessive kinking of the pedicle (2). Platysma myocutaneous flaps were subsequently introduced for intraoral reconstructions by Futrell *et al.* in 1978 (3), but have not gained widespread acceptance. Two flap designs have been described: vertical or superiorly-based flaps and transverse or posteriorly-based flaps (4). The first, which is usually prepared in the ipsilateral neck, is based on the submental branch of the facial artery and may be used to reconstruct the anterior and lateral floor of the mouth, buccal mucosa, retromolar trigone and skin of the lower third of the cheek and parotid region; the second is based on the superior thyroid, occipital, and posterior auricular arteries, and may be used to reconstruct the lower lip, the anterior and lateral floor of the mouth, the ventral surface of tongue, and the skin of the lower third of the anterior face.

The main reason for hesitancy in using this versatile flap is the problematic blood supply which can lead to skin loss and/or orocutaneous fistulas. Some authors have reported flap-related complication rates of 30-40% (5-7), although others have experienced lower complication rates of 10-20%, most of which have been spontaneously resolved (8, 9).

Here we describe our experience on the use of vertical platysma myocutaneous flaps in a group of ten selected patients who underwent reconstructive surgery after the resection of T2-staged oral cancers associated with neck dissection.

### Patients and Methods

The main clinical characteristics of the ten patients (nine men and one woman, with a mean age of 61.9 years, range 33-74 years), who received vertical platysma myocutaneous flaps after undergoing tumour resection between February 2003 and December 2005 at the

*Correspondence to:* Lorenzo Pignataro, MD, Department of Otorhinolaryngological and Ophthalmological Sciences, Fondazione IRCCS Ospedale Maggiore Policlinico, Mangiagalli e Regina Elena, University of Milan, via Francesco Sforza 35, 20122 Milano, Italy. Tel: +39 0250320447, Fax: +39 0250320248, e-mail: lorenzo.pignataro@unimi.it

**Key Words:** Oral cancer, platysma myocutaneous flap, reconstruction, indications.

Table I. *Clinicopathological variables, treatment options and follow-up of the patients.*

Patient	Site	Stage			Dissected levels	Trans-mandibular	Pull-through	Post-op RT	Follow-up
		T	cN	pN					
1	Retromolar trigone	T2	N0	N1	I-IV	yes	no	yes	NED
2	Retromolar trigone	T2	N0	N2b	I-IV	yes	no	yes	DOD
3	Tongue	T2	N0	N0	I-III	no	yes	no	NED
4	Floor of the mouth	T2	N0	N2b	I-IV	yes	no	yes	NED
5	Tongue	T2	N0	N1	I-III	yes	no	no	NED
6	Tongue	T2	N0	N0	I-III	no	yes	no	NED
7	Floor of the mouth	T2	N0	N0	I-IV bilateral	yes	no	no	NED
8	Floor of the mouth	T2	N0	N0	I-IV	yes	no	no	NED
9	Tongue	T2	N0	N1	I-III	no	yes	no	NED
10	Retromolar trigone	T2	N0	N1	I-IV	yes	no	yes	NED

DOD = died from disease; NED = no evidence of disease.

Department of Otorhinolaryngology – Head and Neck Surgery, Milan University School of Medicine are shown in Table I. All of the patients were affected by a T2-staged cN0 primary oral squamous cell carcinoma; none had undergone previous radio- or chemotherapy. The surgical specimens showed node involvement in six cases (N1 in four cases and N2b in two). Diagnosis and grading according to the method of Shanmugaratnam *et al.* (10) indicated that two of the carcinomas were well-differentiated (G1), seven moderately-differentiated (G2), and one poorly-differentiated (G3).

The affected site was the lateral surface of the tongue in four patients, the retromolar trigone in three, and the floor of the mouth in three. The resection was performed using the trans-mandibular approach in seven cases and the pull-through approach in three; four patients also underwent marginal bone resection. All but one of the patients underwent monolateral selective or radical modified neck dissection; a bilateral radical modified neck dissection was performed in one patient. Four patients received postoperative radiotherapy.

**Surgical technique.** The patient was placed with the head hyperextended. In all cases, the flap was prepared before neck dissection in order to avoid injury to the vascular structures, with the size of the skin island placed over the distal insertion of the sternocleidomastoid muscle being based on the hypothesised defect arising from the primary tumour excision. The flap was harvested by means of a sharp dissection with a scalpel in a subplatysmal plane, starting from the muscle attachment to the clavicle and carefully maintaining the dissection planes, and the dissection was continued proximally in a suprplatysmal plane (Figure 1); the external jugular vein was preserved and included in the deep surface of the flap. The oral tumour was then resected and the planned neck dissection performed; at this point, the submandibular branch of the facial artery must be preserved, particularly during level I dissections. The flap was tunnelled through a subcutaneous plane, rotated into the recipient site, and then sutured into position with a single layer of interrupted suture. In order to prevent the formation of a hematoma, careful hemostasis was carried out and two suction catheters were positioned. Care was taken to avoid stretching the flap excessively and creating too much suture tension. Finally, the donor site was closed primarily in layers by advancing the anterior and posterior neck skin.

## Results

Complete wound healing was obtained within six months in all cases (Figure 2), with acceptable neck scars, no limitations on mouth opening, no restriction of movement and no traction on neck skin.

A surgical revision (due to flap detachment) was necessary in only one patient with a retromolar trigone tumour who had undergone a trans-mandibular resection and radical modified neck dissection. The patient was reoperated on and the defect was closed by means of a pectoralis major myocutaneous flap.

No major complications such as nerve lesions or orocutaneous fistulas were observed in the remaining patients, nor did any complications at the donor site occur.

Two patients experienced partial necrosis of the skin island, but the underlying muscles remained viable and only local treatment consisting of bedside debridement was necessary; neither of these patients required surgical revision, nor did the complications compromise their clinical outcome or postoperative programmes. The mean duration of hospitalisation was 12 days and all of the patients achieved adequate swallowing function within two weeks of surgery. Four patients required postoperative radiotherapy, but this did not compromise flap vitality or swallowing function.

Nine patients are still alive with no evidence of disease after a mean follow-up of 26.3 months (range 12-44 months); one patient (number 2, Table I) died from a recurrence in the neck.

## Discussion

Tissue reconstruction is fundamental after ablative surgery for oral cancer as it restores shape and function, and allows

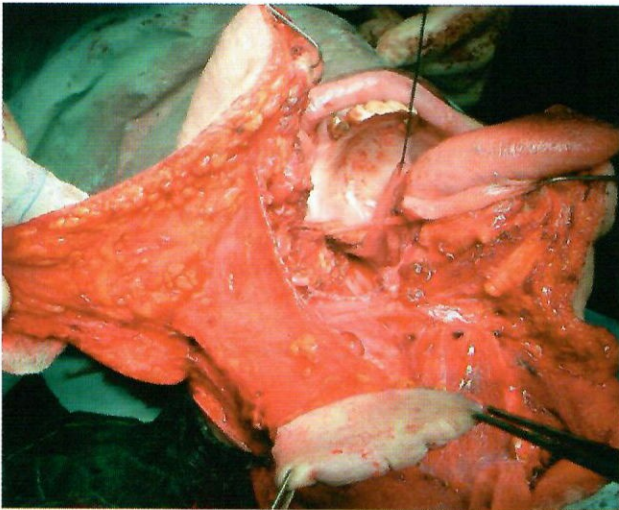


Figure 1. *Platysma myocutaneous flap ready to be sutured after tumour removal.*

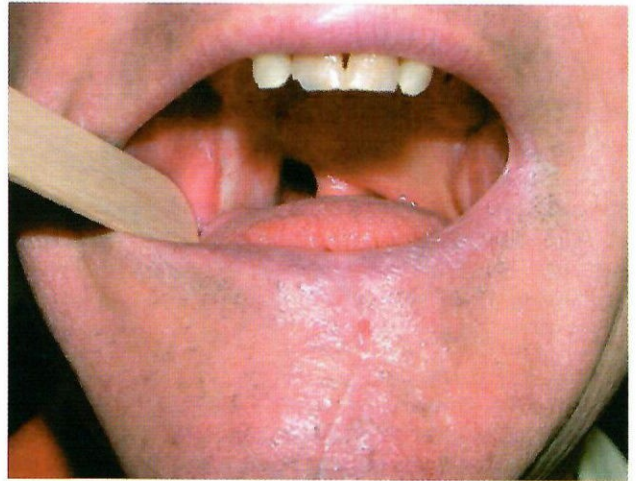


Figure 2. *Intraoral view of the platysma myocutaneous flap reconstruction in a 56-year-old male patient with a retromolar trigone tumour six months after surgery.*

a return to everyday activities. Although emphasis has recently shifted to the use of microvascular-free flaps, easy-to-perform one-stage platysma myocutaneous flaps are a versatile means of reconstructing soft tissue after surgical resection in selected patients affected by oral cancer (11). They have a number of particular advantages: the donor and recipient sites are in the same operative field; the flaps are thin and pliable, easy to harvest and transplant without any specific equipment or skills, and the donor site can be directly closed with an acceptable scar (donor site morbidity is also acceptable). Finally, the flaps can be raised with enough tissue to close most intraoral defects (at least 70 cm<sup>2</sup>) and the time involved in its harvesting is minimal. In our series, all of the flaps adequately reached the intraoral defects, primary donor site closure was possible in all cases, and the skin paddle was large enough to close all of the defects.

The apparent reason for the hesitancy in using platysma myocutaneous flaps is the reported rate of complications (6). The main problem is the loss of skin paddle and the formation of orocutaneous fistulas, which have been considered to be the consequence of ischemic flap failure or obstructed venous drainage (4). Cadaver studies have shown that the submental artery supplies arterial blood, whereas the submental and external jugular veins provide venous drainage. In order to minimise the risk of skin paddle necrosis, we always preserved the submental branch of the facial artery and the external jugular vein, and subsequently ensured complete hemostasis of the recipient site in order to prevent the formation of a hematoma. Finally, any patients who had previously received chemotherapy or

had undergone neck surgery or radiotherapy, or for whom radical neck dissection was planned were not considered candidates for this reconstructive modality. The overall complication rate in our series was 30%; these data are similar to those reported by other authors (3-5, 7, 8). We do not consider ipsilateral level I dissection an absolute contraindication for a vertical platysma myocutaneous flap, but the submental branch of the facial artery should be preserved. If the vascular pedicle has to be sacrificed for oncological reasons, another kind of reconstruction (a microvascular-free or pectoralis major flap) should be considered.

In conclusion, surgeons should consider the option of using a platysma myocutaneous flap when reconstructing soft tissue defects after oral cancer surgery, since the procedure is easy to perform and has a low incidence of complications affecting the donor site and reconstructed area. However, in order to ensure the best results, appropriate patient selection is fundamental: a platysma flap should not be used in patients who have undergone previous neck surgery or radiotherapy, or if a radical neck dissection is planned. Care is required to preserve the external jugular vein and the submental artery, particularly when level I is dissected. Finally, adequate flap preparation and positioning is essential: bone exposure and any communication between the neck and oral cavity at the end of reconstruction should be avoided, the neck tunnel should be wide enough to prevent flap compression, and suture tension must be carefully assessed. With just these few simple indications, the results are optimal in terms of clinical outcome and quality of life.

**References**

- 1 Hara I, Gellrich NC, Duker J, Schon R, Nilius M, Fakler O, Schmelzeisen R, Ozeki S and Honda T: Evaluation of swallowing function after intraoral soft tissue reconstruction with microvascular free flaps. *Int J Oral Maxillofac Surg* 32: 593-599, 2003.
- 2 Delpech JM: *Chirurgie clinique de Montpellier, Vol II*. Gabon, Paris, p. 587, 1828.
- 3 Futrell JW, Johns ME, Edgerton MT, Cantrell RW and Fitzhugh GS: Platysma myocutaneous flap for intraoral reconstruction. *Am J Surg* 136: 504-507, 1978.
- 4 Peng L-W, Zhang W-F, Zhao J-H, He S-G and Zhao Y-F: Two designs of platysma myocutaneous flap for reconstruction of oral and facial defects following cancer surgery. *Int J Oral Maxillofac Surg* 34: 507-513, 2005.
- 5 Coleman JJ, Jurkiewicz MJ, Nahai F and Mathes SJ: The platysma muscolocutaneous flap: experience with 24 cases. *Plast Reconstr Surg* 72: 315-323, 1983.
- 6 Verschuur HP, Dassonville O, Santini J, Vallicioni J and Poissonnet G: Complications of the myocutaneous platysma flap in intraoral reconstruction. *Head Neck* 20: 623-629, 1998.
- 7 Conley JJ, Lanier DM and Tinsley T Jr: Platysma myocutaneous flap revisited. *Arch Otolaryngol Head Neck Surg* 112: 711-713, 1986.
- 8 Esclamado RM, Burkey BB, Carroll WR and Bradford CR: The platysma myocutaneous flap: indications and caveats. *Arch Otolaryngol Head Neck Surg* 120: 32-35, 1994.
- 9 Cannon CR, Johns ME, Atkins JP, Keane WM and Cantrell RW: Reconstruction of the oral cavity using the platysma myocutaneous flap. *Arch Otolaryngol* 108: 491-494, 1982.
- 10 Shanmugaratnam K: Epidemiological studies of cancer in Singapore. *Acta Unio Int Contra Cancrum* 20: 758-762, 1964.
- 11 Zhao Y-F, Zhang W-F and Zhao J-H: Reconstruction of intraoral defects after cancer surgery using cervical pedicle flaps. *J Oral Maxillofac Surg* 59: 1142-1146, 2001.

*Received March 21, 2007*

*Accepted May 21, 2007*